

CHAPTER 3**OSTEOPROTECTIVE EFFECT OF DIFFERENT COMPONENTS OF *MORINGA OLIEFERA* IN OVARECTOMY INDUCED OSTEOPOROSIS MODEL OF WISTAR RATS****INTRODUCTION:**

Postmenopausal conditions arise due to loss of ovarian function and subsequent fall in estrogen levels. This leads to major health related problems for women who suffer from deficient calcium metabolism; arising from less intestinal calcium absorption and increased urinary loss of calcium. Osteoporosis a progressive degenerating disorder that reduces bone mass, especially at the cancellous bone, leading to loss of overall integrity of the bone. This weakens the strength of the bone and increases the risks for fracture (Nozaka *et al.*, 2008). The pathogenesis of osteoporosis is associated with increased osteoclastic bone resorption which is due to the increase in the production of pro-inflammatory cytokines like IL-1 and IL-6 (Xie *et al.*, 2005; Park *et al.*, 2008). These pro-inflammatory cytokines prevents the apoptosis of osteoclasts and diminishes the osteoblast proliferation. This may be attributed to sex steroid deficiency as well as increase in glucocorticoids. Identifying the pharmacological agents which can modulate the osteoclasts and osteoblast cells, so as to preserve or enhance bone mass is the main stay of current pharmacological treatments for osteoporosis.

Recently, various therapies are in use for the treatment of osteoporosis, including calcium supplementation with Vitamin D₃ and Hormone Replacement Therapy (HRT) with estrogen, selective estrogen receptor modulators, calcitonin, raloxifene, amino-bisphosphonates, teriparatide, parathyroid hormone, strontium ranelate, growth hormone, and IGF -1 (Park *et al.*, 2008). Various workers have shown that HRT poses the threat of breast, ovarian and endometrial cancer. Hence, alternative therapies are gaining attendance to discover new remedies for osteoporosis (Xie *et al.*, 2000). One of such alternative therapy, phytotherapy, is earning the importance these days because of its lesser side effects and compliance. Various plants have the potency to check the activity of osteoclastic cells as well to promote osteoblastic cells.

Medicinal plants constitute an effective source of traditional and modern medicines (Mahmood *et al.*, 2005). Traditional herbal medicines have been the integral part of the

medicinal practices in many countries. The long transition of herbal wisdom has employed various herbs for its osteoprotective effect. Thus, natural medicinal plant products are new favorite among the therapeutic substances in the west and drawing attention of scientists and pharmaceutical companies. Phytotherapy is gaining its importance in the new world countries as well. Phytotherapy is considered to be more effective, safe and compliant when compared to classical drugs like strontium renelate or even HRT. Studies conducted at our lab also proved that *Litsea glutinosa*, an ayurvedic herb, checks ovariectomy induced bone loss, ameliorates calcium metabolism, increases the osteoblastic number and activity and prevents the osteoclastic bone resorption (Parikh *et al.*, 2009, Rangrez *et al.*, 2011). Parallel with this work, we started exploring *Moringa oliefera* also for its osteoprotective effect. Previous studies have shown that fruits of this plant are having osteoprotective effect on ovariectomized Wistar rats (Burali *et al.*, 2010). This study gave a preliminary insight into the osteoprotective effect of this plant. However, this study was conducted only on MO fruits and no data was available regarding the osteoprotective effect of the plant leaf and flower, which are marked to have varied pharmacological effects. Hence, we decided to take this study a step further and explore this plant and its components not only for their osteoprotective effect but also for their role in calcium metabolism, as this plant had been a proven source of calcium (Goel *et al.*, 1999).

This study is planned to explore three components of MO, leaf, flower and fruit; for their effect on biochemical markers of bone health, their effect on calcium metabolism, tissue biochemical profile and histo-architecture of the bone.

Materials and Methods:

Experimental protocol: The experimental protocol was approved by IAEC (Institutional animal ethical committee). Thirty 3-month-old virgin female Wistar rats brought from Sun Pharma Advance Research Center (300±20gm) were used for this study. The animals were acclimatized for 8 days before the onset of the experiment to adapt to laboratory conditions (the room temperature was 22±4 °C with a 12 h/12 h light/dark cycle). Then the rats were ovariectomized (OVX) or sham operated after being anesthetized under intraperitoneal injection of sodium pentobarbitol at a dose of 30mg/kg body weight, as described previously (Xiao *et al.*, 2002). The success of the OVX was assessed through vaginal cytology after five days of surgery as described previously (Roveri *et al.*, 2000). Rats were given the lag phase

of 10 days to recover from the stress of operation and experimental animals were divided in 2 main groups, namely control (sham operated) and OVX. OVX animals were daily administered with 200mg/kg of MO extract of three different components. Extracts were prepared as described in chapter II. Every week the feed was checked for any bacterial or fungal infection. If any infection was detected, the entire stock was discarded. Food and water was given *ad libitum*.

Every alternate day food and water intake was measured, and the body weight was recorded. At the end of the study blood was collected by orbital sinus puncture. 0.5 ml blood was collected; serum was separated and stored at -80° C for further analysis. Rats were sacrificed by giving overdose of anesthesia. Rats were dissected, bone, uterus and liver was immediately removed, washed in PBS (pH 7.4), and stored at -80° C for further analysis. Liver and uterus were blotted and weighed. All the assays were carried out using commercial kits purchased from Reckon Diagnostics.

The calcium (Ca) and phosphorus (P) concentrations of serum samples were estimated using standard colorimetric methods and analyzed using automatic analyzer Perkin Elmer as described previously (Beeler and Catrou, 1983; Farrell, 1984; Daly and Ertingshausen, 1972; Gamst and Try, 1980). Serum AIP and TRAcP were estimated using pNPP method (George *et al.*, 1975).

Calcium Excretion rate

For calcium excretion rate, calcium concentration in urine and serum were measured and the ratio of urine and serum calcium was taken into consideration for understanding the effect of this plant on calcium excretion.

Histological evaluation

The histopathological studies were carried for decalcified bone tissue (Fixed in 4% Paraformaldehyde). The tissues were dehydrated in an ethanol series and embedded in paraffin and sectioned at 7 µm thickness (bone). The sections were stained with standard Haematoxylin eosin staining.

Statistical Analysis

Data are expressed as mean values and S.E.M. One-way ANOVA was used to compare data from all groups and Bonferroni post test to compare the results ($p < 0.05$ by the statistical software of Graph Pad PRISM (Version 5.0)). A p value of less than 0.05 was considered statistically significant.

Results:

Body weight and relative organ weight

For this experiment, rats of similar weight group were chosen. After ovariectomy or sham operation there was no significant decrease in their body weight. However, at the end of the study there was marked increase in the body weight of OVX animals compared to sham group. As shown in Table 1, after 8 weeks of study there was significant increase in the body weight of all the ovariectomized animals. Of all the three components of MO, maximum effect was observed with leaf treatment as it significantly reduced the body weight at the end of the study. Both flower and fruit did not have any significant effect on the body weight of the animal (Figure 1). Further maximum alterations were observed in relative uterine weight. As expected, ovariectomy caused significant decrease in the weight of the uterus and relative uterine weight (Table 2). However, no changes were observed in the relative uterine weight of any of the treatment groups. Though relative uterine weight was higher in fruit extract treated group, the data was spastically non significant (Figure 2).

Serum and Urine biochemical markers

Values of serum and urine biochemical markers are listed in Table 3.

Serum Calcium Levels

Serum Calcium is one of the markers used for understanding mineral metabolism in the test subject. Ovariectomy appeared to be reducing the serum calcium levels, where it reduced the serum calcium levels to almost to 50%. Our results are in concordance with previous workers who have reported decrease in serum calcium following ovariectomy. To our surprise, this decrease was poorly defended by leaf extracts of MO. Both flower and fruit of MO improved the serum calcium profile, where flower extracts were found to be having most potent effect (Figure 3).

Urine calcium profile

Urinary excretion of calcium is considered to be more reliable marker of bone resorption, as established by previous workers. Ovariectomy leads to enhanced excretion of calcium in the urine, reaching almost 3 fold calcium compared to control. Treatment with MO components reduced the loss of calcium in the serum, but the data was found to be non significant (Figure 4).

Calcium Excretory rate

It has been established by various authors that the best mean to study calcium metabolism is to study the Calcium excretory rate, which is a more suitable parameter compared to individual serum or urine calcium levels. When we compared the results of serum and urine calcium levels, it was clear that ovariectomy led to increased urinary excretion which was enhanced to 3 fold at the end of 2 months. Out of 3 components of MO, leaves were not having any significant effect on the calcium excretion. Compared to OVX group, MO flower and fruit both reduced the calcium excretory rate, where the fruit was found to be most potent, reducing the excretory rate almost near normal (Figure 5).

Serum Phosphate levels

Phosphate is another byproduct of bone resorption and mineral metabolism. We observed parallel results with previous studies who have reported increased serum phosphate levels following surgical removal ovaries. Serum phosphate levels were ameliorated by all the three components of MO, where the most satisfactory results were due to fruit treatment (Figure 6).

Serum ALP levels

Serum ALP levels are the functional markers of osteoblastic activity and it is used clinically for the detection of variety of bone diseases including osteoporosis. We observed increase in the ALP activity in ovariectomized individuals which showed 300% increase in the ALP activity. This enhanced ALP was indication of increased bone remodeling following loss of estrogen. Plant treatment was successful in ameliorating this parameter. However, the data was non-significant for leaf extract, but it was found to be highly significant for the flower and fruit extract (Figure 7).

Serum TRAcP levels

Serum TRAcP is an osteoclast specific marker used for detection of bone progression and extent of bone resorption. This function marker was found to be high in all ovariectomized animals. Plant treatment lowered the activity of this enzyme and it was found to be most effective with Flower and fruit treatment. MO components were able to reduce this marker to 50% of its value in OVX animals (Figure 8).

Bone and liver biochemical markers

Markers of bone metabolism in liver and bone homogenate were estimated and enlisted in Table 4.

Bone and liver ALP levels

Serum ALP is an enzyme that is contributed many tissues, mainly liver and bone. To nullify the probability that higher serum levels of ALP may be because of Liver, we have estimated ALP activity in both liver and bone. Bone ALP levels were significantly higher in the ovariectomized group compared to normal and plant treatment showed lowered ALP levels with all the three components. However, maximum effect was observed with fruit and flower extracts of MO (Figure 9). No significant changes were observed in liver ALP profile, suggesting that serum ALP levels were mainly attributed to the increased bone ALP levels. Though OVX animals showed elevated liver ALP levels, the data was statistically non significant (Figure 10).

Bone TRAcP levels

Bone TRAcP is the key enzyme which is released during the process of bone resorption via osteoclastic pits. This enzyme plays a vital role in acidification of resorption pits and resorption of bone. As anticipated, Bone TRAcP levels were higher in ovariectomized animals compared to normal. All the three components of MO were found to be reducing the TRAcP activity in bone. However, the data of leaf extract was not found to be having significant effect. Both flower and fruit were found to be having significant inhibitory effect on this osteoclastic marker enzyme. Flower extract was found to be most potent in inhibiting this enzyme, where it reduced the TRAcP activity near 50% compared to OVX group (Figure 11).

Histology of bone

Bone histology is the final confirmation of marker for studying ovariectomy induced bone loss in rats. After a chronic period of estrogen absence, signs of osteoporosis were established in bone. In control groups, we observed healthy compact and cancellous bone. Trabecules were thick and well formed and the bone marrow was found attached to it (Figure 12). In ovariectomized animals the signs of osteoporosis were pertinent. Bone was exhibiting two different structures, compact bone and cancellous bone. No significant damage was seen in compact bone, but the cancellous bone was found to be osteoporotic. The bone trabecules were found to be highly damaged. Thinning and breakage of trabecules was observed at various sites. Histology of OVX animals clearly showed alteration in the bone micro architecture (Figure 13). At high magnification we observed abundance of osteoclastic resorption pits in the bone trabecules. Various sites in the bone showed these results. Figure 14 is one such site showing a site where many osteoclastic resorption pits are observed. These findings were in parallel with Kim and his colleagues (2002) who observed previous results. Treatment with MO components ameliorated these changes. Leaf extract was found to be having lesser effect in improving bone histoarchitecture. Though it prevented the bone loss to some extent, signs of osteoporosis were still observed in the histology (Figure 15). Compared to leaf, both flower and fruit extract showed promising results, where the trabecular bone architecture was found to be much preserved and the features were similar to the control group (Figure 16 and 17). Though signs of damage were seen, the intensity of resorption was much reduced compared to ovariectomized group.

Discussion:

The present study demonstrated that supplementing ovariectomized animals with MO flower and fruit extracts can have positive effect on bone health. Though acclaimed previously to have variety of pharmacological effects, the leaf of MO was not found to be having osteoprotective effect. OVX animals showed weight gain which may be due to lack of estrogen. MO flower and fruit had non-significant effect in reducing the weight gain. Maximum weight reduction was observed with leaf extract treatment, which may be due to presence of alkaloids and tannins in leaf of MO reported previously (Goel *et al.*, 1999). Ovariectomy induced absence of sex hormone initially affects the uterus, leading to uterine atrophy and decrease in the uterine weight. We also observed similar results where the uterine

weight was decreased in OVX animals. MO treatment had no significant effects on the uterine weight, suggesting that constituents of this plant had no estrogenic potential. Our observations are in accordance to with the work done by Roveri *et al.*, (2000) and Xie *et al.*, (2005) who have opined that plants ameliorates OVX induced changes on the bone without affecting the uterus. In the present study the MO extract also did not have the effect on the uterus but potentially inhibits the progression of post menopausal symptoms.

Decrease in serum calcium and increase in urinary calcium post ovariectomy is an established fact and one of the possible reasons for excess bone resorption (Zhang *et al.*, 2002). Furthermore, they have also reported that this could possibly lead to excessive bone resorption. Our study also showed similar results and further when excretory rate was considered, it was observed that calcium excretory rate is very high in ovariectomized animals. Probably this high excretory rate affects the overall calcium metabolism and negative calcium metabolism leads to further progression of the disease. Of the three components of MO, leaf was not having any significant effect on ameliorating the fall in serum calcium but both flower and fruit extracts had significant effects on uplifting serum calcium. Similarly, boosted urinary calcium release was also ameliorated by all the three components, but the data was statistically non significant. But when we considered the calcium excretory rate, it was clear that both flower and fruit extract of MO, had significant effects on calcium excretion, but leaf extracts were not able to counter the calcium excretory rate. These findings also suggested that both flower and fruit extract are having positive effect on calcium balance. These results were similar with Kim and his colleagues (2002) who proved that agents with osteoprotective effect are having positive effect on calcium metabolism. They also established that opposite to serum calcium profile there is increase in serum phosphorus, which is an indication of aggravated mineral metabolism. We also included this parameter in our investigation and showed that all MO components are having positive effect on mineral metabolism.

To investigate the mechanism of action, we evaluated enzyme profile as well. Previous studies in our lab have established that bone is maintained through coordinated activities of osteoblasts and osteoclasts and ovariectomy disrupts this balance, leading to over-activity of osteoclasts, followed by osteoblasts (Parikh *et al.*, 2009). After a lag phase, osteoblasts are not able to keep up with the pace of osteoclasts, leading to an imbalance, where the bone is resorbed much more then it can be synthesized. Two functional markers of this process are

ALP and TRAcP, which are secreted by osteoblasts and osteoclasts respectively (Burmeister *et al.*, 2003; Rangrez *et al.*, 2011). In accordance with this, we also observed that following ovariectomy, there is an increase in the ALP and TRAcP profile. Shevde and co workers (2000) have proved that post ovariectomy rise in TRAcP is because of the disruption of the molecular mechanism of RANK, RANK L and osteoprotegrin pathway which governs the osteoclasts recruitment and activity. And as the bone formation is directly in response to bone resorption, there is also associated increase in the ALP profile. We observed similar results and also observed that MO flower and fruit extract are having potent effect on both the markers. This parallel fall in both the markers clearly suggest that both flower and leaf ameliorate the damage caused by estrogen deficiency. To confirm that the elevation in serum ALP levels is because of bone remodelling only, we estimated liver ALP levels also, which showed no significant variation between the plant treated group and control group. Further investigation in bone tissue profile showed parallel results with serum profile and showed that both fruit and flower of this plant are having potent effect on the changes induced by ovariectomy. Furthermore, histological observations also showed that ovariectomy induced damage to histoarchitecture of the bone and the damage was severe in cancellous bone. This may be because of the excessive bone resorption that is occurring due to aggressive osteoclastic cells which resorb the bone and on the counterpart; the osteoblasts are not able to keep up with resorption. Treatment with flower and fruit extract reversed ovariectomy induced changes and the bone became healthier as evident by the presence of well formed trabecules and lesser sites for bone resorption. Though leaf extract also showed some effect in histology, from the overall results it was concluded that leaf extract is having no significant osteoprotective effect.

It has been established that phytochemical profile of MO leaf, flower and fruits are different and they exhibit different pharmacological property. Various studies have proved that both flower and fruit are having a milieu of various pharmacological agents which are having anti inflammatory activity (Aguwa and Nwanko, 1988; Ezeamuzie 1996). Proliferation and maturation of osteoclasts follows a pathway that involves variety of inflammatory cytokines. As the fruit and flower are having robust anti inflammatory activity, they might be directly affecting the inflammatory pathways of development of osteoclasts. In a recent study by Penolazzi and his team (2008) proposed that plants with potent anti inflammatory activity are having osteoprotective effect. Our results also supported his work and showed that MO flower

and fruit are having osteoprotective effect. Furthermore, an array of studies have proved that both flower and fruit are rich of flavonoids and other phytochemicals which are having potent anti oxidant property (Bharali *et al.*, 2003; Kumar and Pari, 2003; Bajpai *et al.*, 2005; Pari *et al.*, 2007; Owusu-Ansah *et al.*, 2011). Osteoclastic bone resorption involves secretion of variety of digestion enzymes and acids. These antioxidants probably serenens the bone resorption process and adds to the osteoprotective effect of this plant.

In conclusion, our results suggest that of all the three components of MO, leaf, flower and fruit; both flower and fruit are having positive effect on the ovariectomy induced bone loss. As both these components are having an array of phytochemicals with anti inflammatory as well as antioxidant effect, consumption of this plant may be helpful in prevent postmenopausal osteoporosis.

Table 1: Increase in body weight in different treatment groups

Week progression	Control	Ovx	Leaf	Flower	Fruit
1	248.330±3.330	242.500± 5.280	245.830± 4.170	240.000±3.330	240.000±3.330
2	260.830± 3.610	250.000± 6.110	250.830±3.890	245.830±3.890	245.830± 3.890
3	273.330± 4.170	270.830±5.830	266.670± 3.610	262.500±3.330	262.500±3.330
4	282.500± 3.890	285.830± 4.170	275.830± 6.110	275.000±3.060	275.000± 3.060
5	291.670± 5.000	295.830±5.000	291.670± 4.170	284.170±2.500	284.170±2.500
6	295.830± 5.280	313.330± 3.610	307.500 ± 5.280	305.000±2.220	305.000± 2.220
7	305± 4.170	332.500±5.280	317.500± 3.610	320.830±4.170	320.830±4.170
8	315 ± 2.780	345.830± 6.110	337.500± 5.830	338.330±4.720	338.330± 4.720

Values were expressed as Mean ± S.E.M. * - $p < 0.05$; ** - $p < 0.01$; *** - $p < 0.001$.

Table 2: Relative uterine weight in different experimental groups.

	Control	Ovx	Leaf	Flower	Fruit
Relative uterine weight	0.001± 0.0001	0.00022**± 0.000152	0.00024± 0.000225	0.000235± 0.000205	0.00029± 0.00027

Values were expressed as Mean ± S.E.M. * - $p < 0.05$; ** - $p < 0.01$; *** - $p < 0.001$.

Table 3: Serum/Urine Biochemical markers

Parameters		Control	Ovx	Leaf	Flower	Fruit
Serum Profile	AIP	54.663± 4.57	124.569***± 6.33	118.455± 6.336	79.258***±8.336	68.456***±4.336
	Calcium	8.811± 0.189	5.465***± 0.262	6.608± 0.229	8.466***±0.293	7.456**±0.233
	Phosphate	7.910±0.569	18.223**±1.892	10.336*±0.689	11.569**±0.881	10.236**±0.233
	TRAcP	6.583±0.556	15.166***± 0.651	9.336*±0.812	7.986**± 0.556	8.456*±1.265
Urinary calcium		4.325± 0.986	12.669*±1.336	11.566±1.256	8.569± 2.336	7.255 ±1.236
Calcium Excretion rate		0.518±0.110	1.307*± 0.235	0.977± 0.145	0.618*± 0.105	0.655*± 0.129

Values were expressed as Mean ± S.E.M. * - $p < 0.05$; ** - $p < 0.01$; *** - $p < 0.001$.

Table 4: Bone and Liver biochemical markers

Treatment groups		control	Ovx	Leaf	Flower	Fruit
Bone	AlP	379.077± 7.874	624.836**±20.622	541.372* ± 15.748	443.104** ±11.997	411.566**±11.23
	TRAcP	6.583± 0.556	15.166***±0.651	9.336± 2.669	7.986** ± 0.669	8.456*± 1.365
Liver	AlP	79.081± 12.367	99.787±20.593	70.335± 18.844	65.176± 19.883	78.127± 24.734

Values were expressed as Mean ± S.E.M. * - $p < 0.05$; ** - $p < 0.01$; *** - $p < 0.001$

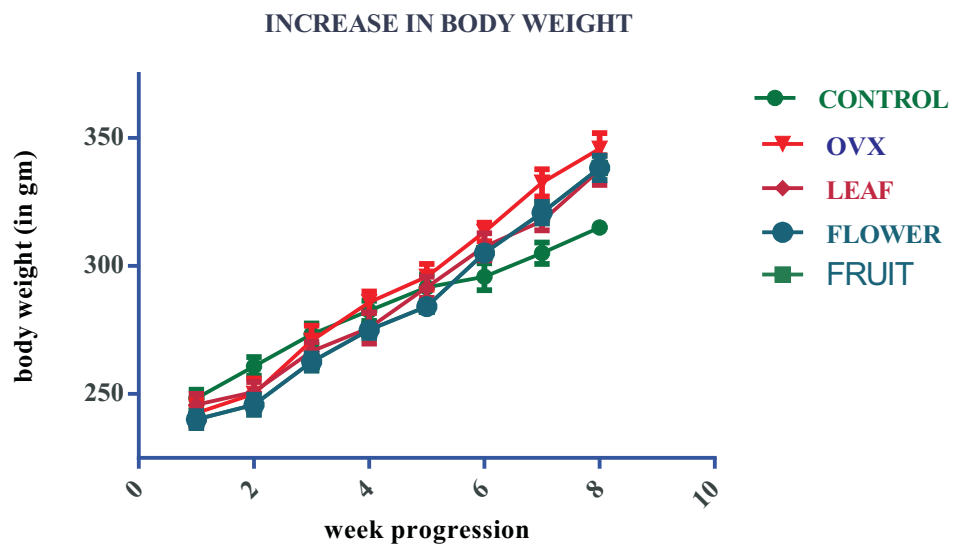


Figure 1

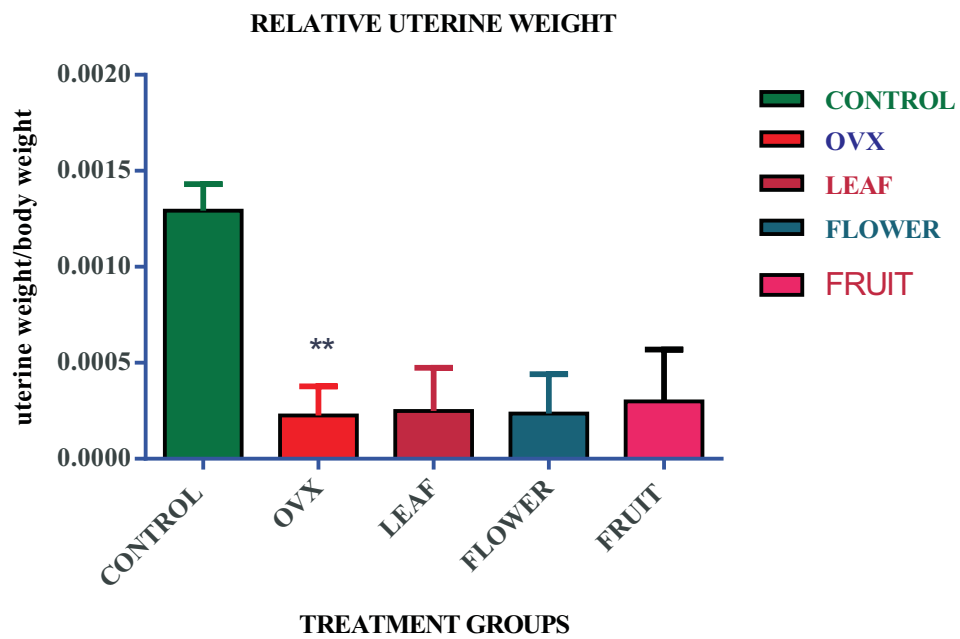


Figure 2

Figure 1: Body weight gain; Figure 2: Relative uterine weight

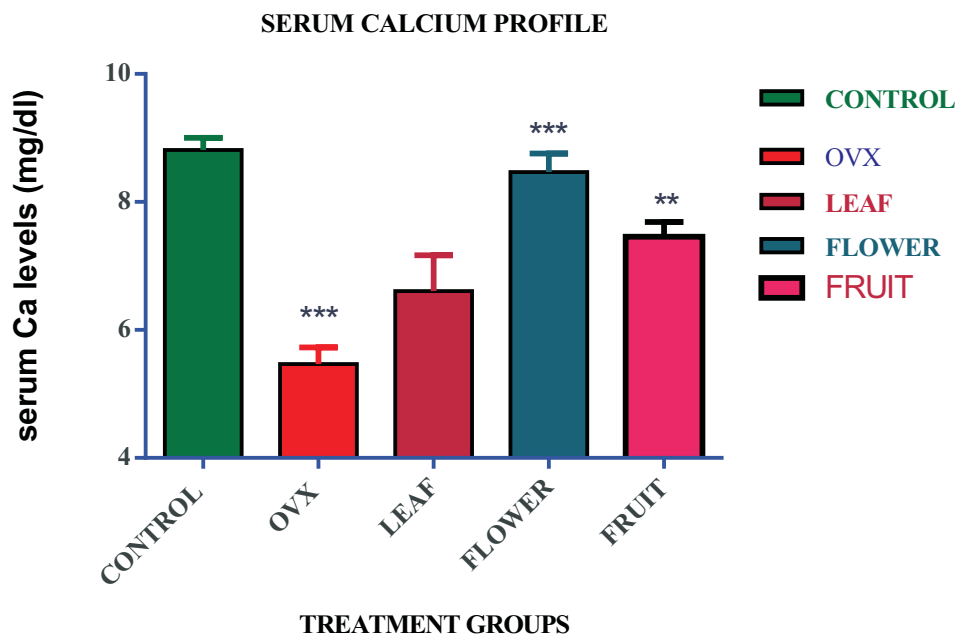


Figure 3

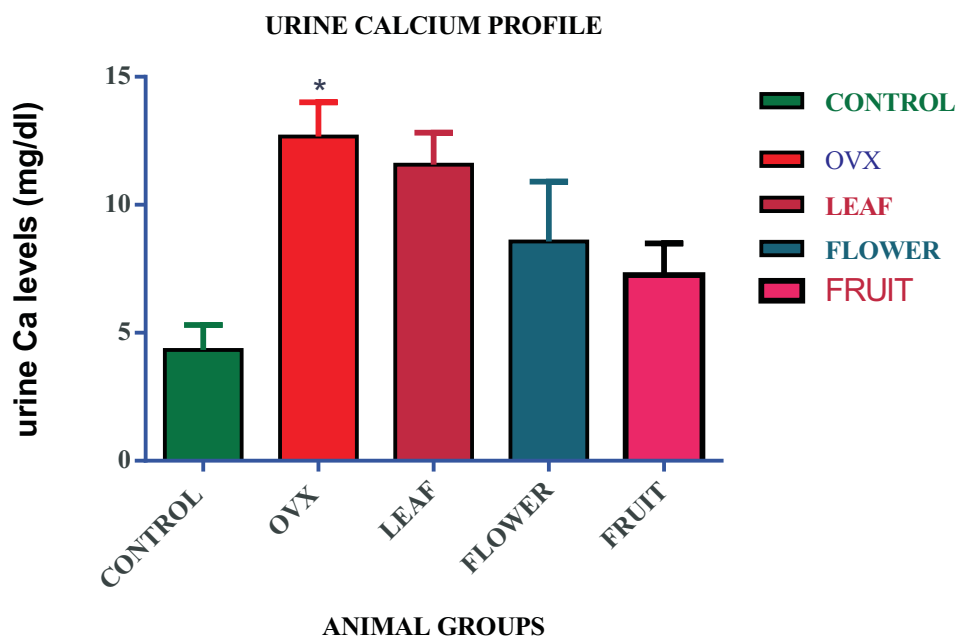


Figure 4

Figure 3: Serum Calcium profile; Figure 4: Urine Calcium Profile

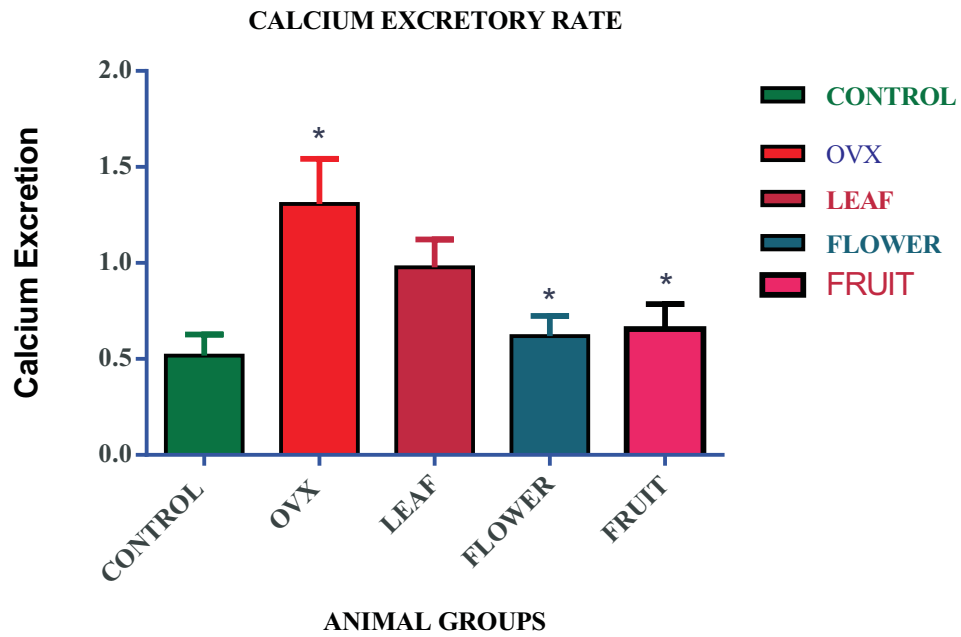


Figure 5

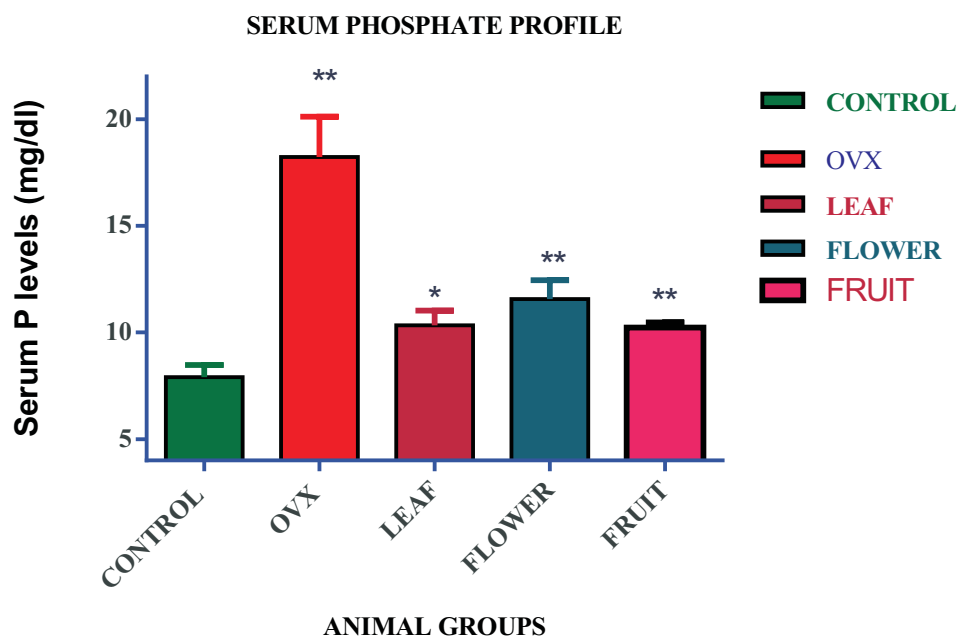


Figure 6

Figure 5: Calcium Excretory rate; Figure 6: Serum Phosphate levels

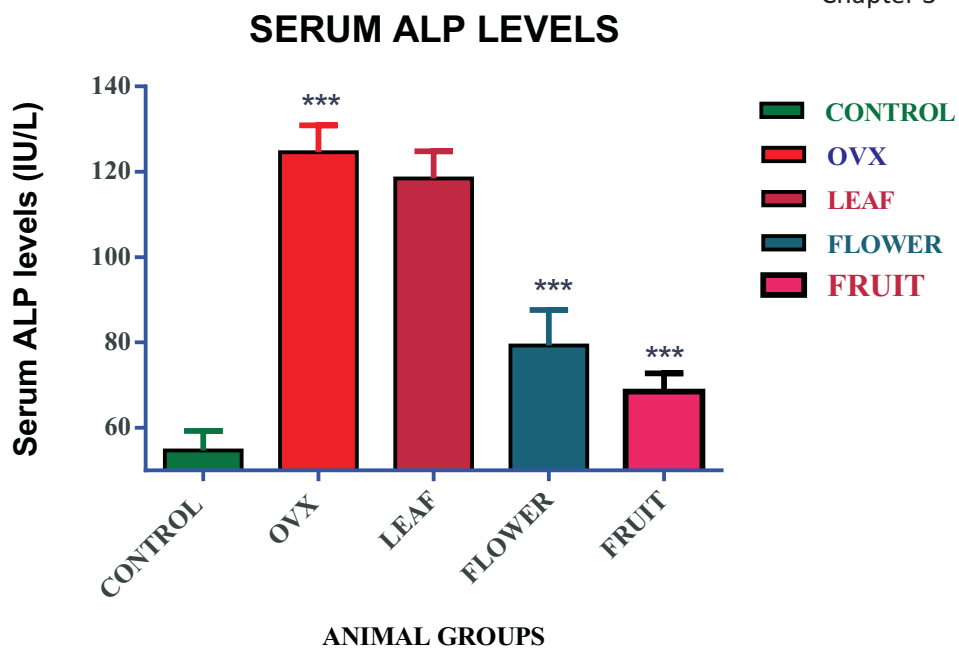


Figure 7

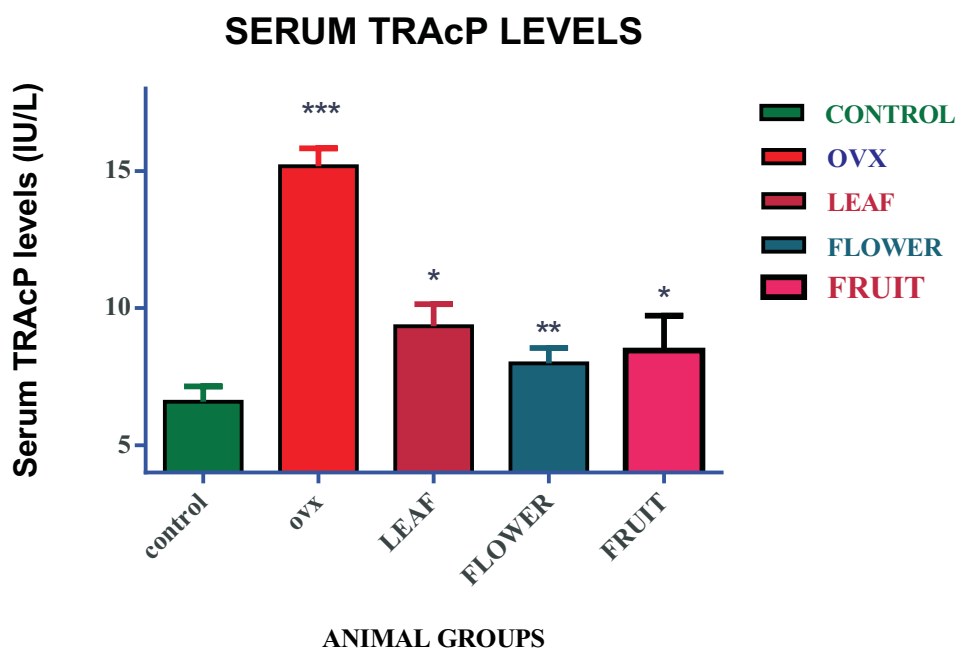


Figure 8

Figure 7: Serum ALP Profile; Figure 8: Serum TRAcP Profile

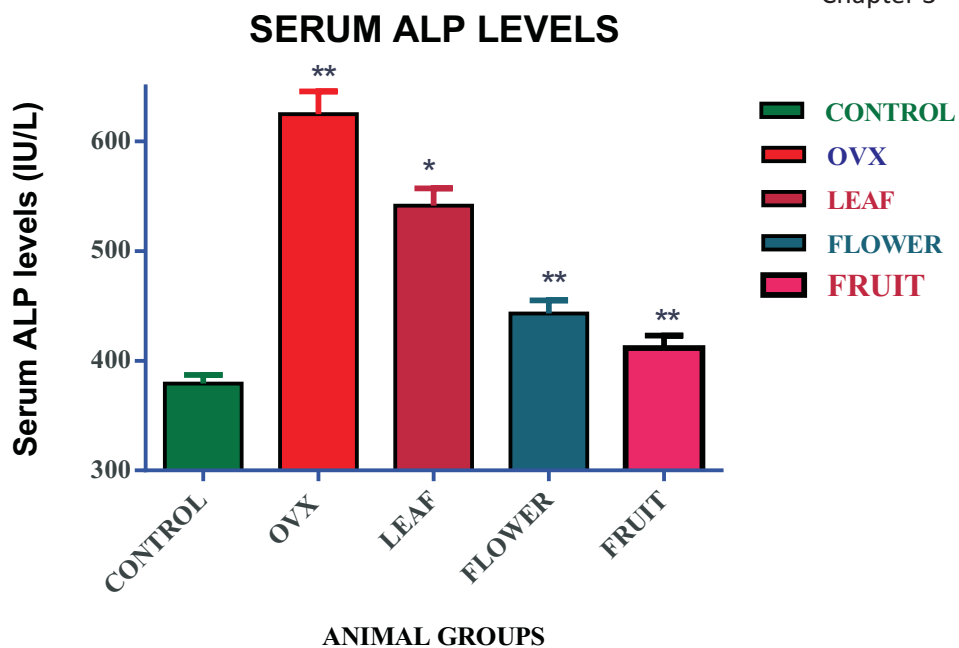


Figure 9

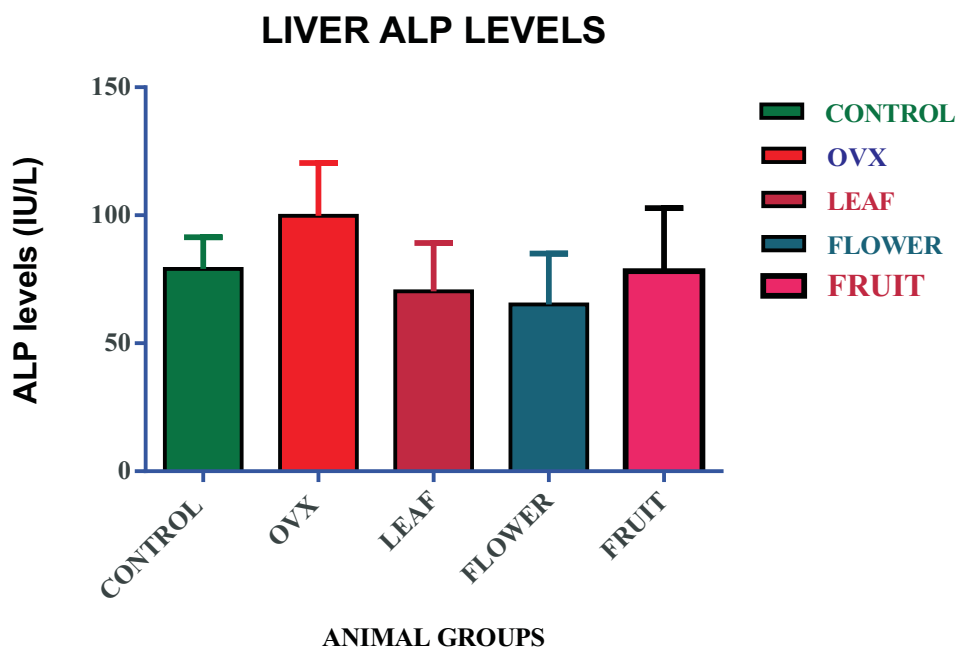


Figure 10

Figure 9: Bone ALP levels; Figure 10: Liver ALP levels

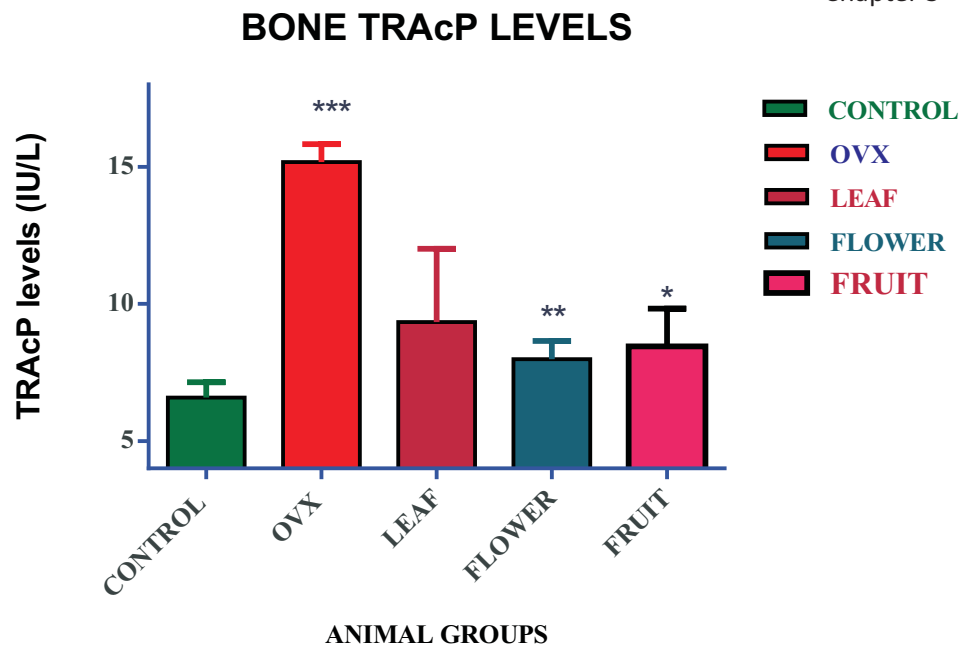


Figure 11

Figure 11: TRAcP activity in bone;

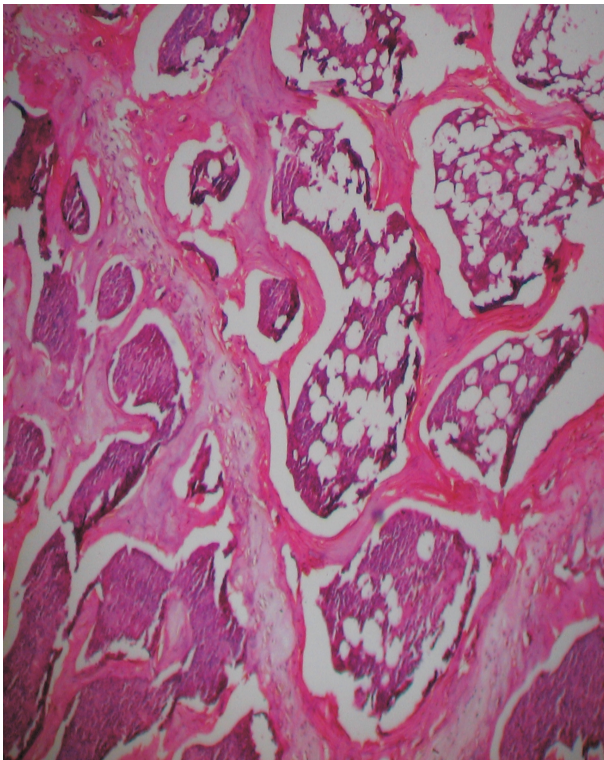


Figure 12

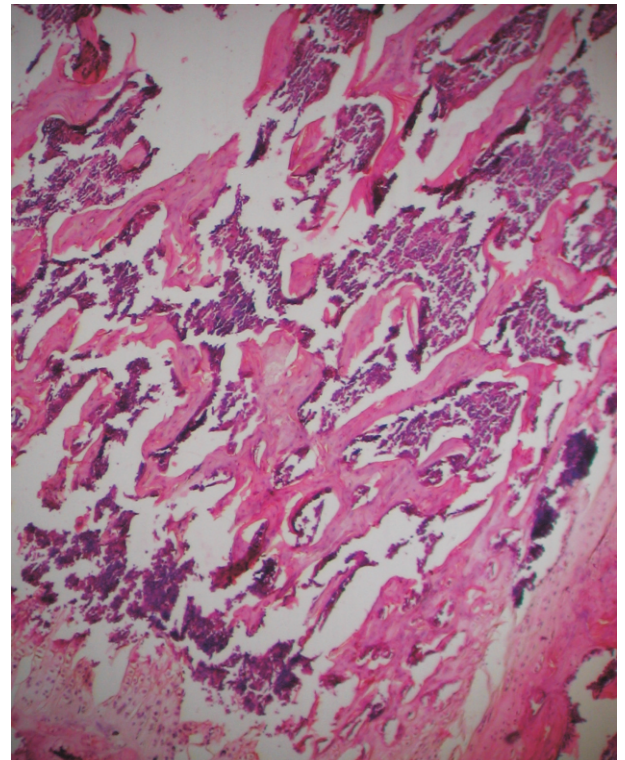


Figure 13

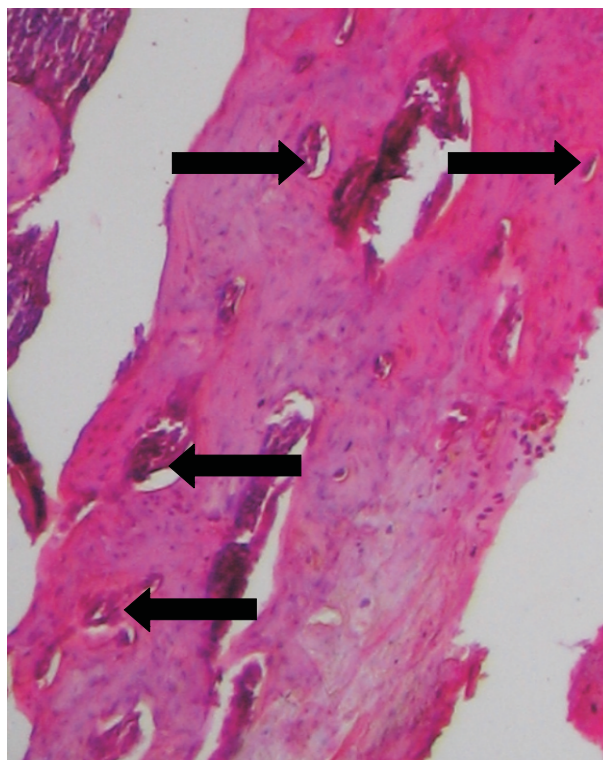


Figure 14

Figure 12: Histology of control bone showing normal histo architecture of bone with well formed trabecules, no resorption signs and well arranged bone marrow. Figure 13: Histology of ovariectomized rat bone showing damage to trabecules, thinning of trabecules, loss of associated bone marrow, and generalized alteration of bone histo architecture. Figure 14: Histology of ovariectomized bone at high magnification showing more number of osteoclastic resorption pits and loss of mineralized matrix from the bone.

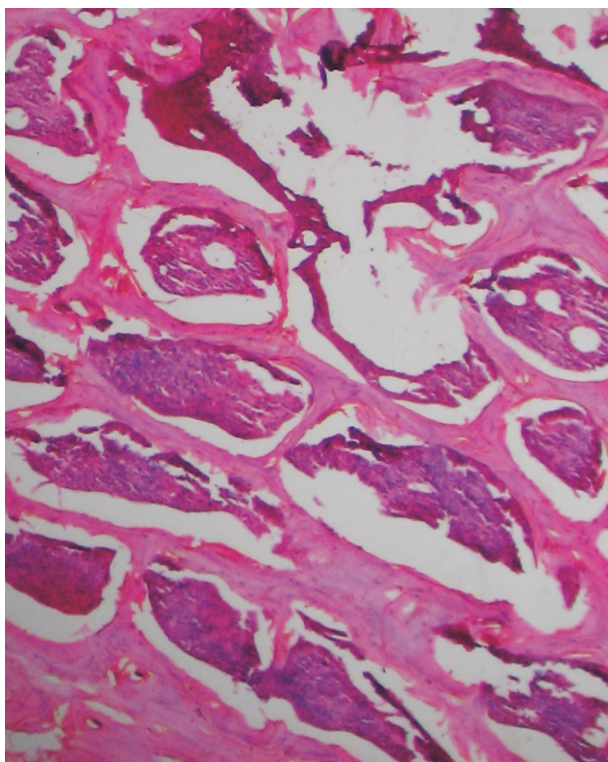


Figure 15

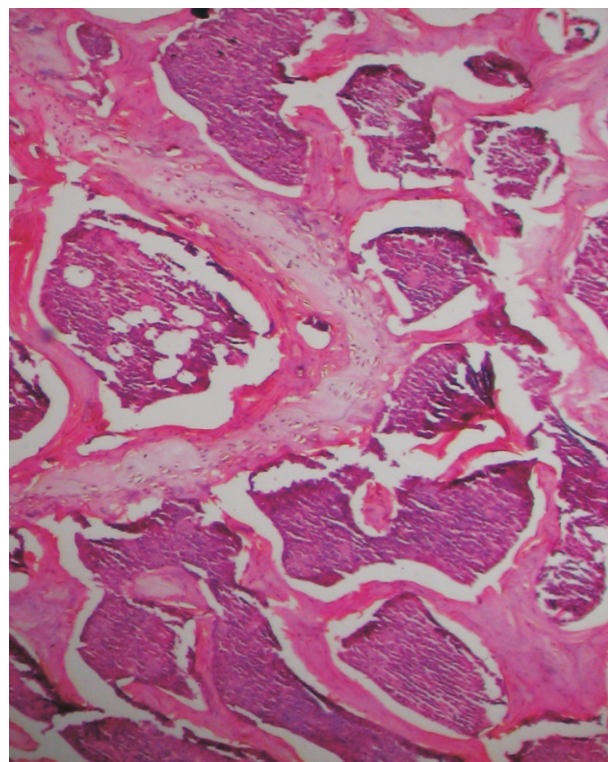


Figure 16

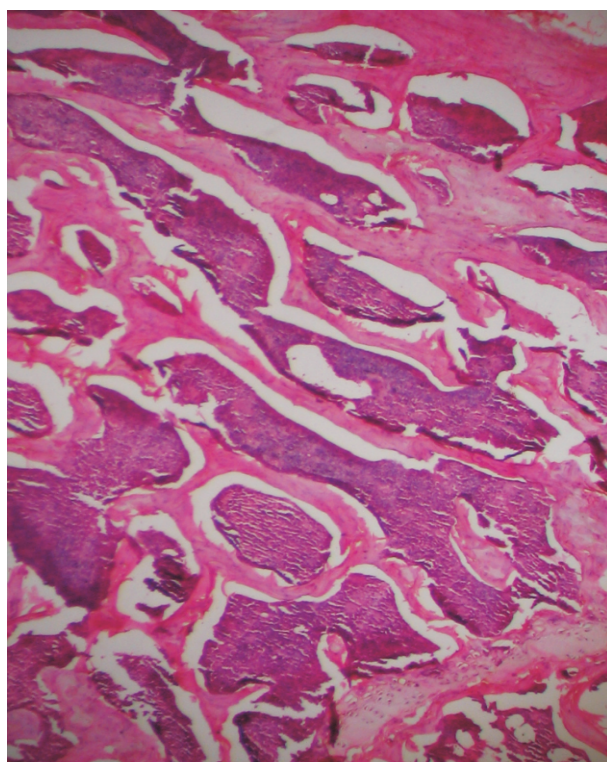


Figure 17

Figure 15: Histology of leaf extract treated group showing improvement histoarchitecture, but still signs of trabecular bone loss were pertinent. Figure 16: Histology of flower extract treated group showing thicker trabecules, lesser sites of bone damage and associated bone marrow. Figure 17: Histology of fruit extract treated group showing healthier trabecules, associated bone marrow and less signs of bone damage.