

**“A CADAVERIC STUDY OF MORPHOLOGY OF INTERNAL ILIAC ARTERY &
VARIATION IN ITS BRANCHING PATTERN WITH ITS CLINICAL SIGNIFICANCE”**

ABSTRACT OF THESIS SUBMITTED TO



THE MAHARAJA SAYAJIRAO UNIVERSITY OF BARODA

FOR THE DEGREE OF
DOCTOR OF PHILOSOPHY
ANATOMY
FACULTY OF MEDICINE

BY
DR. RASHMI BHARDWAJ

UNDER THE GUIDANCE OF
DR. VASANT H. VANIYA
PROFESSOR & HEAD
DEPARTMENT OF ANATOMY
MEDICAL COLLEGE, BARODA



DEPARTMENT OF ANATOMY
MEDICAL COLLEGE BARODA
THE MAHARAJA SAYAJIRAO UNIVERSITY OF BARODA.

2022

TITLE OF THE STUDY: “A CADAVERIC STUDY OF MORPHOLOGY OF INTERNAL ILIAC ARTERY & VARIATION IN ITS BRANCHING PATTERN WITH ITS CLINICAL SIGNIFICANCE”

INTRODUCTION: -

Anatomy is derived from the Greek word “anatome” which means cutting up. It is one of the core basic science subjects. The discipline of anatomy, while providing the fundamental knowledge of the structure of the human body, also underpins the study of physiology and pathology as well as a host of clinical specialties including clinical medicine, surgery and radiology. Human cadaveric dissection has been used as the core teaching tool in anatomy for centuries and has become a greatly acknowledged fact that good medical or surgical practice could only be based on adequate knowledge of human anatomy which can only be learned from cadaveric dissection.

The human body is a very complicated and sophisticated unit. Variant anatomy is a field of anatomical science that concerns the abnormalities of the human body structure. Anatomical variations are not only very interesting and thought-provoking for anatomists but also of principal concern for clinicians. The variations in vascular system are quite common. Internal iliac artery (IIA) found in pelvic cavity is an area of the interest in this study.

The internal iliac artery is the “artery of the pelvis”. It supplies most of the blood to the pelvic viscera, namely; rectum, urinary bladder, prostate and seminal vesicle in male, uterus in female and musculoskeletal part of the pelvis. However, it also supplies branches to the gluteal region, medial thigh region and the perineum including erectile tissues of the penis and the clitoris.

IIA is also called as hypogastric artery according to the older terminology is given off by the common iliac artery (CIA) at its bifurcation anterior to the pelvic brim at the level of the sacroiliac joint. The artery descends posteriorly within the pelvic cavity towards the greater sciatic foramen. At the upper border of this foramen, it ends by dividing into anterior and posterior divisions (Bergman et al., 2015, Tunstall, 2016). The visceral branches of the anterior

division are superior vesical artery (SVA), inferior vesical artery (IVA), middle rectal artery (MRA), uterine and vaginal arteries. The last two branches are present in females, wherein the vaginal artery replaces the inferior vesical artery. The parietal branches of the anterior division are obturator artery (OA), inferior gluteal artery (IGA), and internal pudendal artery (IPA). The branches from the posterior division are all parietal, namely, iliolumbar artery (ILA), lateral sacral artery (LSA), and superior gluteal artery (SGA) (Standring and Gray, 2008).

The concentration of organs and anatomical structures within the closely packed confines of the pelvis makes the study of vascular patterns and their variations of paramount importance not only for the anatomists but also for surgeons, obstetricians and gynaecologists, urologists, vascular surgeons and radiologists. Moreover, internal iliac artery exhibits great number of variations unlike the external iliac artery which is constant and relatively simple in its morphology. The embryological explanations for the variations in the arterial pattern are based on unusual selection of channels from a primary capillary plexus, wherein the most appropriate channels enlarge while others retract and disappear thereby establishing the final arterial pattern.

The present study has been undertaken to observe not only the variation in origin, length, diameter, branching pattern of internal iliac artery but also levels of origin of important individual branches of IIA like obturator artery, iliolumbar artery, superior vesical, middle rectal and uterine artery. Isolation of internal iliac artery and tracing of the major branches will provide add information about it and thereby enlightening the radiologists and operating surgeons on every aspect of IIA in Indian population.

AIM OF THE STUDY

The aim of the study was to describe the morphometric & morphological features of internal iliac artery and to describe the origin & anatomical variations of individual branches of internal iliac artery like obturator artery, superior vesical artery, iliolumbar artery, inferior gluteal artery, internal pudendal artery & middle rectal artery.

Objectives:-

Objectives of the present work are:

- To locate the site of origin of internal iliac artery.
- To identify the vertebral level of origin of internal iliac artery.
- To measure the length of the artery.
- To measure the caliber of the artery.
- To describe the course & relation of internal iliac artery.
- To determine the termination level & mode of internal iliac artery.
- To find out branching pattern of internal iliac artery
- To classify the branching pattern of internal iliac artery according to Adachi's classification.
- To describe the origin of obturator artery
- To determine the origin of iliolumbar artery.
- To find out the origin of inferior gluteal artery.
- To locate the origin of superior vesical artery
- To detect the origin of internal pudendal artery.
- To identify the origin of middle rectal artery.
- To find out & report anatomical variations associated with internal iliac artery & its branches.
- To compare data with other similar studies.

SHORT REVIEW OF LITERATURE:-

- In 1825, Herbert stated that the internal iliac artery (IIA) is a branch of the common iliac artery (CIA). The internal iliac artery is the main artery of the pelvis but is shorter, thicker and smaller than the external iliac artery. During embryological development the IIA appears as a continuation of CIA before EIA development and is twice large: its length varies from one to two inches.
- It arises at the bifurcation of the common iliac artery anterior to the lumbosacral junction (L5/S1) and descends along the convexity over the anterior (ventral) surface of the sacrum to the superior border of the greater sciatic foramen.
- Generally, the internal iliac artery supplies the pelvis including the walls and viscera, as well as the perineum, hip, gluteal region and medial (adductor) compartment of the thigh.

- Previously, **Herbert (1825)** in an older description of the IIA divisions did not refer to anterior and posterior trunks, rather he described the trunk as having numerous branches classified into the internal surface of the pelvis, pelvic viscera and extra pelvic branches based on their terminal course.
- The first classified branches to the internal surface of pelvis are the iliolumbar artery and lateral sacral artery. The second classified branches to pelvic viscera are hypogastric artery or umbilical, vesical and middle rectal arteries. The third classified branches are the gluteal artery, sciatic artery, internal pudendal and obturator arteries.
- Then, **Power (1862)** gave a different classification, which were internal and external arteries based on whether they remain inside or were distributed outside the pelvis, respectively. The first class has a different classification in males to females. In males, the internal arteries are iliolumbar, lateral sacral, middle rectal, vesical and umbilical arteries. In females, this class has same division except it has additional branches which are vaginal and uterine arteries. The second class is external arteries are gluteal, pudendal (pudic), sciatic and obturator artery.
- A different approach was adopted by **Jastschinski (1891)** into three groups based on size of artery. The first group of large calibre arteries are the superior gluteal, inferior gluteal and internal pudendal arteries; the second group of medium caliber arteries is the obturator artery; the third group of small calibre arteries are iliolumbar and lateral sacral arteries.
- More recent authors have classified the internal iliac artery branches into visceral branches supplying the urinary bladder, prostate, seminal vesicles, ejaculatory ducts and rectum in males, and the urinary bladder, ovaries, uterus, vagina, urethra and rectum in females (Testut 1948; Williams 1995). In addition, previous studies have also classified the internal iliac artery branches supplying the gluteal region, posterior and medial compartment of thigh and hip joint (Fredet 1899; Rouviere 1967) into the extra pelvic branches of the internal iliac artery.
- Limitations of previous classifications: These classifications have not been used to any great extent because of deficiencies in their descriptions; for example, some of arteries supply both intra and extra pelvic structures. The size of the artery varies from one cadaver to another.
- A relatively simple classification of the Internal iliac artery has been described as dividing into two trunks, anterior and posterior trunks (Carter 1867; Sharpey et al 1867; Wilson 1868)

➤ **Adachi (1928)** was the first to classify the variation of internal iliac artery into 5 types :

Type I: The superior gluteal artery arise independently from the internal iliac artery whereas the inferior gluteal and internal pudendal vessels arise from a common trunk into two forms above and below the pelvic floor which are Type Ia and Type Ib. respectively.

Type II: The superior and inferior gluteal arteries arise from a common trunk whereas the internal pudendal artery arise independently. The gluteal common trunk divides into two forms above and below pelvic floor which are Type IIa and Type IIb respectively.

Type III: The superior and inferior gluteal arteries and the internal pudendal artery arise from the internal iliac artery independently

Type IV: The superior and inferior gluteal arteries and the internal pudendal artery arise from a common trunk of the internal iliac artery.

Type V: The internal iliac artery trunk gives the internal pudendal and superior gluteal arteries from a common trunk whereas the inferior gluteal has a separate origin.

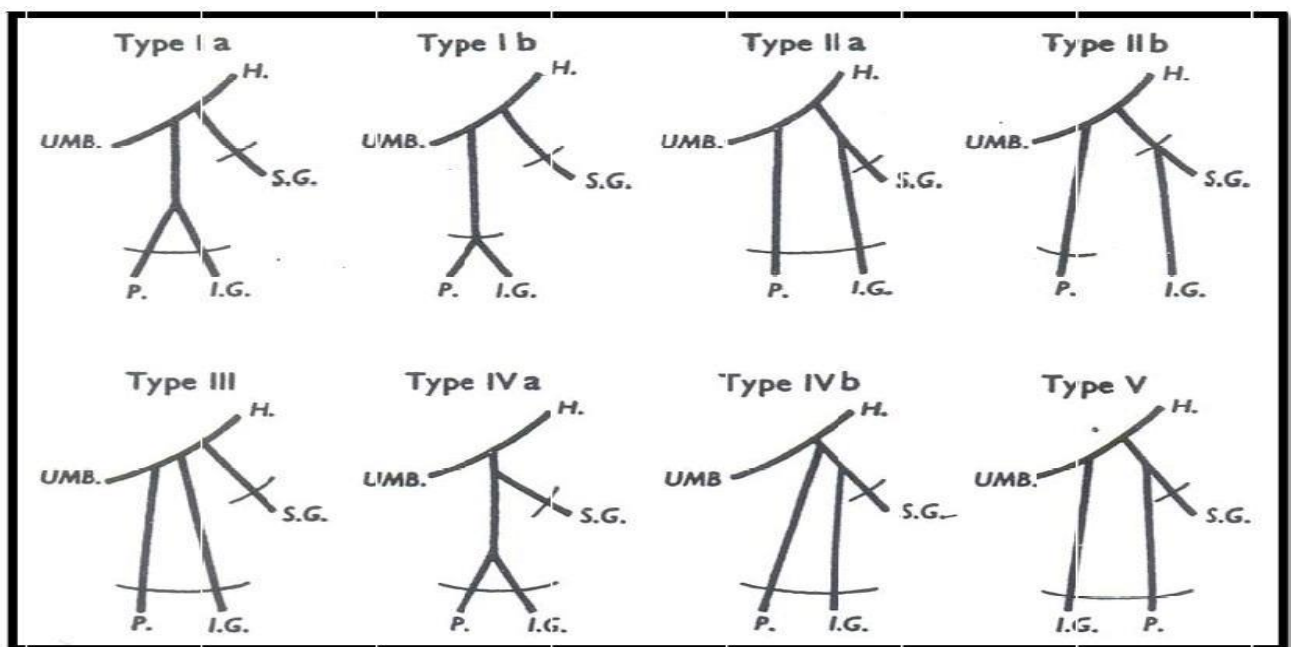


Fig. 1: Adachi's types H- internal iliac artery; I.G- Inferior gluteal artery; P- Internal pudendal artery; S.G- Superior gluteal artery; UMB - Umbilical artery

- **Ashley and Anson (1941)** have updated this classification by adding the umbilical artery to the three previous arteries used in the Adachi's classification, which in turn was a modification of Lipshutz (1916) classification excluding the obturator artery.
- **Yamaki et al (1998)** classification is a modification of the Adachi's classification, he reported that the artery divided into a common trunk with the superior gluteal artery instead of the genitourinary branches (80%).
- However, based on a radiological review of 197 cases **Pelage et al (1999)** established a classification of the internal iliac artery reporting that it terminated as two main trunks (anterior and posterior) in 77% of cases and into three main trunks in 14% of cases including posterior branches a common trunk of the internal pudendal and inferior gluteal artery and genitourinary branches. In addition, Pelage also stated that in 3% of cases the internal iliac artery has four or more terminal divisions, in 4% of cases the internal iliac artery remains as a single main trunk, while in 2% of cases the internal iliac artery had no systematic termination.
- **Bilhim et al (2011)** using angio Magnetic Resonance and digital angiography, angiocomputed topography in 42 specimens.

Clinical application

- Knowledge of internal iliac artery and its branching pattern is not only important for the anatomists but also for surgeons, obstetricians and gynaecologists, urologists, vascular surgeons, orthopedics and radiologists.
- Bilateral internal iliac artery ligation is an effective lifesaving method to control obstetrical and gynaecological haemorrhage and avoids a hysterectomy. While operating on pelvic organs, eg: in haemorrhoidectomy, rectal malignancies, the knowledge of internal iliac artery, its branching pattern and its variations is important for surgeons.
- Intractable haemorrhage during transurethral resection of prostate surgeries can be controlled by ligation of internal iliac artery, where no definitive bleeding point is detectable.
- Angiographically directed arterial embolization is very effective in controlling the haemorrhage and now widely practiced because it is a minimally invasive technique.
- The intentional ligation of internal iliac artery is also done in the treatment of endovascular repair of aortoiliac aneurysms.

- The iliac crest flap pedicled on the ilio-lumbar artery, a branch of posterior division of internal iliac artery, is being used as a reliable bone flap.
- Surgeons dealing with laparoscopic herniorrhaphy must also be conscious of unexpected sources of haemorrhage, such as from an aberrant obturator artery that crosses the superior pubic ramus while dealing with direct, indirect inguinal, femoral or obturator hernias and take appropriate precautions to avoid injury during dissection of the Bogros space and mesh stapling onto Cooper's ligament.
- Vascular variations have always been a subject of controversy as well as curiosity, because of their clinical significance
- Prior knowledge of the anatomical variations is beneficial for the vascular surgeons ligating the internal iliac artery or its branches and the radiologists interpreting angiograms of the pelvic region

MATERIALS & METHOD :

Data collection procedure:

This was a descriptive cross-sectional analysis study carried out after obtaining approval from ethics committee Medical College Baroda, Gujarat. Twenty Five properly embalmed and formalin fixed adult cadavers (11 males and 14 females) were selected for the study. All the available specimens, did not have any visible external abnormalities in their pelvic region were included. Any cadavers with previously operated in pelvic region which may prevent the morphometric analysis were excluded from the study. Dissection was done under the guidance and supervision and observations were made after dissecting the cadavers.

Data collection methodology:

- A horizontal incision through the abdomen at the fourth lumbar vertebral level was made. The whole pelvic was dissected to expose the common iliac arteries. After evisceration the Common Iliac artery (CIA) was traced down to their point of bifurcation into the external & internal iliac arteries. The external iliac artery (EIA) extending in line with CIA towards the inguinal ligament and internal iliac artery (IIA) directed towards the pelvic cavity.

- Then, the peritoneum was removed from the bladder, uterus (in female), rectum and the lateral pelvic wall from each side of the pelvis.
- The vertebral level of bifurcation of CIA into EIA and IIA was noted, as the level of origin of the internal iliac artery.
- The horizontal distance from the point of origin of internal iliac artery to the midsagittal plane of the pelvis was recorded. Midsagittal plane was represented by the line connecting the middle of the pubic symphysis with the middle of the lumbosacral promontorium (Fatu C et al., 2006).
- Careful dissection was done to trace the internal iliac artery to its point of terminal branching into anterior and posterior divisions or branches.
- The relation of the internal iliac artery with the sacroiliac joint was observed as either being medial, anterior or lateral. The other relations of the artery with the surrounding structures mainly ureter and the internal iliac veins were also noticed.
- The length of the artery was measured from the point of origin at the bifurcation of the common iliac artery till the terminal branching point of internal iliac artery where it divides into anterior and posterior divisions.
- In cases where the internal iliac artery divides into various branches instead of two divisions, the termination was considered at the point where the superior gluteal artery arises, according to Adachi classification.
- External diameter of the artery was measured at the middle segment between the origin and termination of the artery (Fatu C et al., 2006).
- The mode of termination of internal iliac artery was identified and noted. It usually terminates by bifurcating into anterior and posterior division but sometimes other patterns of termination like trifurcation or ramification into multiple branches were also seen.
- The occasional branches that are arising from the common trunk before division into anterior and posterior division were dissected, traced & noted.
- The level of termination of internal iliac artery was determined by measuring the distance from the superior margin of the greater sciatic foramen to the point of division of artery into anterior and posterior trunk or branches (Havaladar PP et al., 2014).
- All measurements were made using a well-calibrated digital Vernier caliper and documented.

- For accuracy measurements was taken twice and then the average of both values were considered.
- The individual branches (parietal, visceral) arising from the anterior and posterior divisions was dissected, parietal branch were traced up to their exit from the pelvic cavity and visceral branch were traced till they reach their destination organ.
- The large-caliber parietal branches of the artery, i.e., the superior gluteal artery, inferior gluteal artery, and pudendal artery were identified.
- The branching pattern of internal iliac artery was identified and classified according to Adachi's classification into 5 types.
- Origin of individual branches of internal iliac artery like obturator artery, superior vesical artery, iliolumbar artery, inferior gluteal artery, internal pudendal artery & middle rectal artery were identified & recorded.
- Relevant photographs of the dissected specimen were taken using a 16-megapixel digital camera for record.
- A pattern of variation that have occurred at the level of origin and division of the main trunk, anomalous branches that have aroused from both anterior and posterior divisions, any absence of definitive branches from the anterior and posterior division was noted.

Data analysis: -

- The parameter was measured by using digital Vernier caliper in millimeters (mm) & relevant photographs of the dissected specimen were taken using a 16-megapixel digital camera.
- The data obtained was recorded in a standardized data collection sheet.
- Data was exported to Microsoft Excel (Version 2021), descriptive statistics was used to determine the frequencies of the nominal variables and range, mean, standard deviation of the numerical data.

OBSERVATION & RESULTS:

Total Fifty formalin fixed adult human pelvic halves were dissected (Right 25, Left 25) with known gender. 22 were Male Specimen & 28 were Female Specimen.

1. **Vertebral Level of origin of internal iliac artery :**

- The internal iliac artery takes origin from different vertebral levels varying from L4\ L5 junction to S1. Notably, the most common vertebral level of origin was at the between L5&S1 intervertebral disk level (23/50).
- Bilateral Asymmetry was also observed in vertebral level of origin of internal iliac artery in many cases. There is a well-marked tendency for the left common iliac artery to bifurcate at a lower vertebral level than the right.
- It was observed that the origin of internal iliac artery between L4 and L5 was found only in males. There is also the tendency in females to bifurcate at a lower level & range of variability was also less in female.

2. **Distance of origin of the internal iliac artery to the midsagittal plane**

- The horizontal distance from the origin of the internal iliac artery to the mid-sagittal plane varies from 23.65mm to 43.26mm in the present study.
- The average distance of the internal iliac artery from the mid-sagittal plane was 33.42mm with Standard Deviation of 4.83. In majority of specimens (60%) the distance ranged from 29 to 38 mm
- There is a variation in the distance of the internal iliac artery from the midsagittal plane in relation to gender, in females distances are larger from the midline.
- Average distance from the midsagittal plane is more on left side than right

3. **Relation of internal iliac artery with sacroiliac joint**

- Internal iliac artery in most cases lies medial to the sacroiliac joint.
- In one female specimen internal iliac artery lies lateral to the sacroiliac joint on both sides. It is related directly anterior to the joint in 28% cases.

4. **Length of internal iliac artery**

- The length of the internal iliac artery varies considerably.
- The length of IIA ranged from the minimum measure of 11.21 mm to the maximum of 66.37 mm. However, in majority of specimens (44%) the length of IIA ranged from 30mm to 40 mm. The mean length was found to be 38.16 ± 11.22 mm.
- There was no statistically significant difference in the dimensions above between the left and right sides of the pelvis

5. Diameter of internal iliac artery

- The external diameter of internal iliac artery in males range from 3.63mm to 8.45mm (Figure 5.4) & in females it varies from 4.15mm to 8.27mm
- In majority of specimens (40%) the diameter of IIA ranged from 7 to 8 mm The mean diameter of 6.83 ± 1.24 mm was observed in this study.
- It was observed that in female caliber were larger than males, which may be exists to accommodate the demands of the pelvic excavation of the female genital organs.
- There was no statistically significant difference in the dimensions above between the left and right sides of the pelvis

6. Termination patterns of internal iliac artery

- In most of the Cases (80%) the internal iliac artery terminates by dividing into anterior and posterior trunks. In the present study other terminal branching patterns such as trifurcation and ramification into multiple branches were also found

7. Level of division of internal iliac artery in respect to greater sciatic foramen (GSF)

- In the current study cases were observed in which internal iliac artery terminates 2.5 – 2.0 cm proximal as well as 1cm distal to superior border of Greater Sciatic Foramen.
- In 72% cases the level of termination of internal iliac artery was above the Greater Sciatic Foramen.

8. Type of branching pattern of internal iliac artery according to adachi's classification

- Our study revealed the predominance of type Ia pattern of internal iliac artery in both male & female. Only in a single male cadaver Type V branching pattern was observed on right side
- No case of Type IIb & Type IV of Adachi's classification found in our study.
- The order of incidence of Types in the present study was $I > III > II > V$ instead of $I > II > III > IV > V$ by Adachi's classification.

9. Origin of obturator artery

- The present study shows that the origin of the obturator artery was highly variable. Out of 50 pelvic halves studied, 31 pelvises (62%) showed variations.
- Obturator artery was most frequently a direct branch of the anterior division of the internal iliac artery, in 19 specimens (38%), obturator artery arise from posterior division of internal iliac artery in 26% of specimens either as a separate branch in 16% cases, with Superior

Gluteal Artery (6%), or with Iliolumbar Artery (4%) , Obturator Artery was found arising from external iliac artery or its branch inferior epigastric artery in 36% of cases in the present study.

10. Origin of inferior gluteal artery

- In present study origin of Inferior gluteal artery was from anterior division in majority of cases (90%) which is either independently from anterior division 26% or through a common trunk with Internal Pudendal artery 64%
- In 8% cases of present study inferior gluteal artery arise from a gluteal common trunk with superior gluteal artery from Posterior division. In a single case 2% inferior gluteal artery arise from Obturator Artery which was arising from Posterior division of the internal iliac artery

11. Origin of iliolumbar artery

- The origin of the iliolumbar artery observed in our study, were grouped into 3 different categories. In majority of specimen 52% the site of origin of the iliolumbar artery was as a separate branch from the Posterior division, 38% (19) from the trunk of the internal iliac artery, 4% (2) from the single trunk with obturator artery from posterior division, and 6% (3) it was absent.
- Iliolumbar artery is present as a single branch in 45 out of 50 (90%) specimen. In a single cadaver on both sides there were double origins of the Iliolumbar artery from two different points, one direct from the trunk of the internal iliac artery & other from the Posterior division of the internal iliac artery. Iliolumbar artery was found absent in 3 specimens (6%).

12. Origin of internal pudendal artery

- In majority of cases (64%) Internal Pudendal artery arises through a common trunk with Inferior gluteal artery which corresponds with Type 1 Adachi classification of branching pattern of internal iliac artery.
- Internal Pudendal artery arises from anterior division independently in 34% specimen which includes both Type II & Type III of branching pattern of Adachi classification.
- On very rare instance the internal pudendal and superior gluteal arteries from a common trunk (Type V of Adachi classification) which was found in 2% cases of our study.

13. Origin of superior vesical artery

- In a male cadaver on the left side the superior vesical artery arises from obturator artery which was also having an aberrant course & origin from external iliac artery instead of internal iliac artery. While on the right side of same cadaver the superior vesical artery arises from usual anterior division of internal iliac artery, a single such case was observed among 50 pelvic halves.
- In our study superior vesical artery arises as a single branch as well as multiple branches from anterior division of internal iliac artery. In majority of the cases 68% superior vesical artery arises as a two branches.

14. Origin of middle rectal artery

- In our study Middle rectal artery was found arising from a common trunk with internal pudendal artery & inferior gluteal artery from anterior division of internal iliac artery

CONCLUSION

Our study concludes that the internal iliac arteries show considerable variation in its morphology and morphometry. Unique termination via trifurcation and ramification may be present. These variations of the internal iliac artery could have resulted from genetic, structural or mechanical causes. The clinical implications of these findings are manifold especially in the context of diagnostic and interventional radiology and pelvic surgery.

Surgeons and interventional radiologists performing procedures on the internal iliac artery, or its branches, or related structures should be mindful of these variations.

Our study reveals the variations in internal iliac artery anatomy as against the standard depiction of the artery.