

CHAPTER 7

STRUCTURE OF THE PECTORALIS OF A FLYING MAMMAL (BAT) FOR
COMPARISON

From the work presented hitherto it has become evident that the development of the red, narrow, fat-loaded variety of fibres in the breast muscle seems to be a clear case of adaptional differentiation. The birds and ^{Quetzal?} bat are both flying animals indulging in sustained muscular activity and it was thought desirable to make similar studies on the pectoral muscle of the bat (Hipposideros speciosus) for comparison.

Material and Methods

The animal was decapitated and pieces of the pectoralis major muscle were cut out for the different preparations. For general observations, fresh frozen sections were cut and mounted in isotonic sucrose solution. For the measurement of the diameter of the fibre the preparations were made in the same way except that the muscle piece was removed from the killed animal only after it showed no response to external stimulus. For the study of the distribution of the fibres, the sections were projected on the screen of a microphotographic camera and exposed directly on the photographic printing paper. For the measurement of the diameter of the fibres the sections were observed under oil-immersion and the diameter measured using a scaled ocular and a micrometer slide.

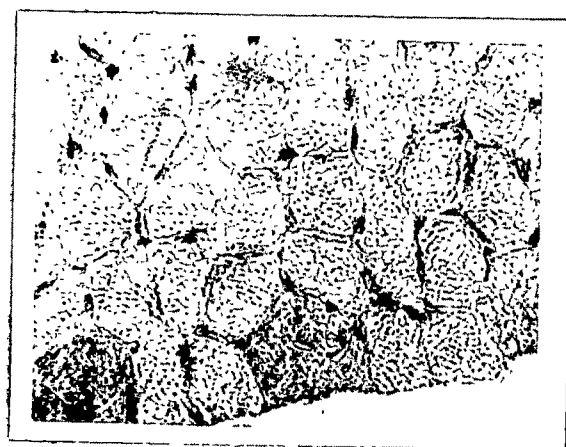
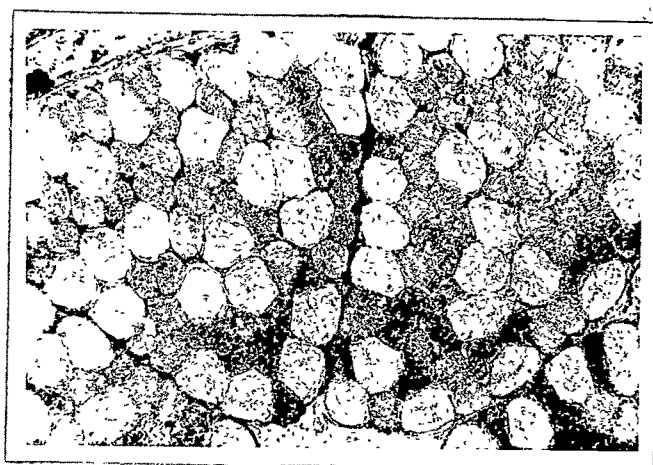
Fresh frozen sections treated with Janus Green B in isotonic solution to stain mitochondria were mounted in isotonic sucrose solution and immediately photographed.

To demonstrate lipids in the fibres, frozen sections of the piece of muscle, fixed in Baker's calcium-formol for a week and embedded in gelatin, were cut and stained with Sudan Black (saturated solution in 70% alcohol).

Paraffin sections of the muscle pieces fixed in Rossman's fluid at 0°C were stained with Best Carmine to stain glycogen. The control sections were incubated in saliva. Prior to staining, all the sections were coated with celloidin.

Observations and Discussion

The pectoralis major muscle arises from the keel-like expansion (of the ⁵body) of the sternum and the fibres run laterally and forwards converging in a flat tendon, which is inserted at the medial base of the deltoid ^{of humerus}ridge. Anteriorly, the muscle is thick, but more posteriorly it becomes thinner and ^{is}thinnest towards the posterior border. The transverse sections of the muscle show that there are two distinct types of fibres as in the pigeon breast muscle. The fibres in the interior of the muscle consist predominantly of the narrow ones (the ratio of broad to narrow being 1:10) while in the superficial part (fig. 8.1) there is a gradual increase of the broad fibres, with the result that the broad ones are comparatively more there (the ratio of broad to narrow being 1:2). In the posterior part of the muscle the narrow fibres are not ^{as}~~so~~ numerous as in the anterior region.



Structure of the pectoralis major of the bat (H. speoris)

Fig. 8.1 Untreated t. s. of the superficial region of the fresh frozen muscle showing two types of fibres. $\times 140$

Fig. 8.2 T.s of the muscle embedded in paraffin is stained with Best Carmine and Hemalum. Two white broad fibres on the outer border of the fasciculus and a portion of a third similar fibre on the right uniformly stained, show considerably larger amount of glycogen in them than the others. $\times 600$


Fig. 8.3 L. s. of the fresh frozen tissue stained with Janus Green B. A portion of the white broad fibre with few mitochondria is seen on the left, whereas on the right is seen the red narrow fibre showing numerous deeply stained mitochondria and unstained refractile fat globules. $\times 1400$

The marginal position of the broad fibres in a fasciculus is maintained only in the superficial region of the muscle (fig. 7.4), even though not so distinctly as in the pigeon. The broad (white) fibres have a diameter of $59\ \mu$ while the narrow (red) ones ^{are} $39\ \mu$. (These values represent the mean diameter of a large number of fibres.)

In the section stained with Janus Green B, the mitochondria are considerably more numerous and larger in the narrow fibres than in the broad ones (fig. 7.3). In the narrow fibres numerous unstained fat globules of various types are also visible. It was also noticed that, in the fresh frozen sections the broad fibres present more and larger ice crystals^a in them than the narrow ones.

In preparations stained with Sudan Black the mitochondria appear lightly stained whereas the fat globules are deeply stained. In the white fibres the fat globules are extremely sparse and (to the contrary) in the red ones (fig. 7.4). The fat globules are disposed in longitudinal rows between the areas of Cohnheim but they do not ~~however~~ seem to be associated with either the transverse bands of the fibres or the mitochondria.

Those sections stained for glycogen show that all broad fibres ³ ~~(without exception)~~ possess a much higher concentration of glycogen in them than the narrow ones (fig. 7.2). The staining was uniform and no polarisation of glycogen due



Structure of the pectoralis major of the bat (H. speoris).

Fig. 8.4 L. s. stained with Sudan Black showing an unstained white fibre in between two deeply stained red fat-loaded ones. In the former only lightly stained mitochondria situated at the dark bands are seen, whereas in the latter the deeply stained fat globules are seen prominently and distinctly from the lightly stained mitochondria. $\times 1400$

Fig. 8.5 T. s. embedded in gelatin and stained with Sudan Black. Parts of three white fibres are seen on the top. The red ones show greater concentration of Sudan Black. The areas of Cohnheims in the red fibres are lightly stained. In between these areas, deeply stained lipoid inclusions show up in the photograph as dark dots. The white fibres are practically unstained.

$\times 600$

to fixation was observed.

It has been shown that in the pectoralis major muscle of the pigeon, the white fibres are broad and glycogen-loaded, whereas the red ones^{are} narrow and fat-loaded and that the latter have a much higher mitochondrial content than the former. In this respect the structure of the pectoralis major of bat (Hipposideros speoris) resembles that of the pigeon.

Bullard (1912), and recently George and Jyoti (1955a), reported the presence of only ~~one~~ the red type of fibres in the breast muscle of bat. The present study has shown the presence of two distinct types of fibres, as in the pigeon breast muscle, and also the possibility of the occurrence of such variations in the architecture of the pectoralis muscle as reported in ~~the case of~~ birds,^{also} existing in different bats. That fat is^{also} the chief fuel^{in the bat also,} when the pectoralis is subjected to prolonged exercise as in birds, has been shown by George and Jyoti (1957).

Summary

1. The pectoralis major muscle of the bat (Hipposideros speoris) consists of two distinct types of fibres, a white, glycogen-loaded, broad variety poss^{ess}ing few mitochondria, and a red, fat-loaded, narrow variety having a considerably larger mitochondrial content.
2. ^A Comparision is drawn between these fibre types and those of the pigeon breast muscle.